



# Pomegranate (*Punica granatum* L.) Peel and Probiotics Modulate Oxidative Stress and Intestinal Microbiota Associated with Chemically Induced Colon Cancer in High-Fat-Diet Fed Rats

Rachida Benguiar<sup>1</sup>, Rachida Benaraba<sup>2</sup>, Houari Hemida<sup>3</sup>, Sarah Bouamar<sup>1</sup>, Ali Riazi<sup>1\*</sup>

<sup>1</sup>Laboratory of Beneficial Microorganisms, Functional Foods and Health, Department of Food Science, Faculty of Nature and Life Sciences, Abdelhamid Ibn Badis University, Mostaganem, 27000 Algeria

<sup>2</sup>Laboratory of Improvement and Valorization of Local Animal Productions, Department of Nature and Life Sciences, Faculty of Nature and Life Sciences, Ibn Khaldoun University, Tiaret, 14000 Algeria

<sup>3</sup>Institute of Veterinary Science, Ibn Khaldoun University, Tiaret, 14000 Algeria

**Corresponding Author:** Ali Riazi, PhD, Professor, Laboratory of Beneficial Microorganisms, Functional Foods and Health, Department of Food Science, Faculty of Nature and Life Sciences, Abdelhamid Ibn Badis University, Mostaganem, 27000 Algeria. Tel: +213-550 204365, Fax: +213-45 366501, Email: ardz22003@yahoo.fr

Received January 24, 2020; Accepted April 3, 2020; Online Published December 27, 2020

## Abstract

**Introduction:** Colon cancer is a real public health problem. Pomegranate peel and probiotics are thought to be important therapeutic nutritional strategies for colon cancer prevention. The aim of this study was to evaluate the modulation effect of pomegranate peel alone or in combination with probiotics against the oxidative disorders and intestinal dysbiosis associated with chemically-induced precancerous lesions in rat colon.

**Materials and Methods:** Thirty-six male Wistar rats were divided into six groups: Groups 1 and 2 were negative DMH-untreated control rats receiving standard diet (SD) for G1 and high-fat diet (HFD) for G2; while groups 3 and 4 were positive DMH-treated control receiving SD for G3 and HFD for G4; Groups 5 and 6 were DMH-treated and fed with 2.5% pomegranate peel-supplemented HFD diet in the presence of probiotics ( $4 \times 10^9$  CFU/kg diet) for G6. After 16 weeks of experimentation, biochemical analysis, oxidative parameters, histopathological examination of the colon and microbial analysis were performed.

**Results:** Findings showed that pomegranate peels and probiotics induced a significant increase in ferric reducing the ability of plasma levels by 67% and reduction in the malonaldehyde content by 66%. In addition, this treatment helped to improve the histological architecture of the colon in the rats of groups G5 and G6, in comparison with the HFD positive DMH-treated control group (G4). Furthermore, this treatment was also the most effective in decreasing the pathogenic bacteria amount involved in the intestinal dysbiosis (7 to 43%) and increasing in beneficial bacteria (60%).

**Conclusions:** These results suggest that pomegranate peel and probiotics act as a chemopreventive agent against preneoplastic lesions.

**Keywords:** *Punica granatum* L., Oxidative Stress, Intestinal Microbiota, Probiotics, Colon Cancer

**Citation:** Benguiar R, Benaraba R, Hemida H, Bouamar S, Riazi A. Pomegranate (*Punica granatum* L.) peel and probiotics modulate oxidative stress and intestinal microbiota associated with chemically induced colon cancer in high-fat-diet fed rats. J Appl Biotechnol Rep. 2020;7(4):215-223. doi:10.30491/JABR.2020.121479.

## Introduction

Colon cancer is the third most common cancer worldwide after lung and breast cancers.<sup>1</sup> Risks of this pathology are strongly linked to environmental, genetic and hormonal factors as well as lifestyle and type of diet. Moreover, it is generally accepted that a strong relationship may exist between colon cancer and dietary imbalance.<sup>2</sup> Therefore, many studies have suggested that type and amount of fat diet are associated with the risk of colon cancer.<sup>3-5</sup> It has been clearly established that the excess dietary energy provided by high fat diet enhances the reactive oxygen species (ROS) production, thus causing oxidative stress which lead to DNA damage.<sup>6</sup> Chemically-induced models of colon carcinogenesis in rats are adequate

for the study of induction and prevention of colon cancer. Actually, 1,2 Dimethylhydrazine (DMH) is a colon specific carcinogen, it is metabolized in the liver by dehydrogenation to form metabolic intermediates such as azoxymethane and methylazoxymethanol. These metabolites give rise to methyl-carbonium ion which methylates DNA to generate oxidative stress and causes aberrant crypts foci.<sup>7</sup> It is also involved in the dysbiosis of the intestinal microbiota which is associated with colon cancer. Increasing studies reveal that intestinal microbiota imbalance (dysbiosis) plays an important role in the etiology of colon cancer, through processes involving inflammation or mutagenic toxins.<sup>8,9</sup> Some experimental and clinical evidence suggest that probiotics, prebiotics or

their combinations (synbiotics) modulate the gut microbiota composition and contribute to protective effects against colon cancer progression.<sup>10,11</sup> Probiotics are viable microorganisms that, when administered in adequate amounts, confer a health benefit to the host.<sup>12</sup> The dietary supplements of lactic acid bacteria as a preventive of colon cancer have received special attention. Prebiotics are substrate that selectively stimulate the growth of beneficial bacteria in colon conferring a health benefit.<sup>13</sup>

Colon cancer is usually associated with persistent oxidative stress and ROS which react with DNA, lipids and cellular proteins. Thus, the ROS attack leads to lipide peroxidation, and genetic alteration to contribute carcinogenesis.<sup>14</sup> Therefore, the organism possess endogenous antioxidant defense system against these ROS damaging such as superoxide dismutase (SOD), glutathione peroxidase (GPx), glutathione reductase, catalase, glutathione (GSH) and vitamins.

The modulation of oxidative stress by natural antioxidant compounds is currently an efficient approach in colon cancer prevention. Consequently, pomegranate polyphenols could be considered as promising candidates for colon cancer chemoprevention.

The pomegranate (*Punica granatum* L.) is a fruit which has been widely studied due to its bioactive compounds and its remarkable therapeutic properties.<sup>15</sup> The consumption of this fruit generates considerable quantities of by-products, indeed, pomegranate peels are frequently rejected without recovery. As a result, pomegranate peel contains important phytochemical compounds such as tannins and anthocyanins.<sup>16</sup> These bioactive compounds possess different biological activities such as scavenging of free radicals, inhibiting microbial growth and reducing the risk of cardiovascular, cerebrovascular diseases and certain cancers.<sup>15,17</sup> They can also have antimicrobial effects that may influence the composition of the intestinal microbiota. Furthermore, Li et al<sup>18</sup> reported that pomegranate ellagitannin promote the growth of beneficial bacteria such as *Bifidobacterium* and *Lactobacillus* and inhibit the growth of *Bacteroides*, clostridia, and Enterobacteriaceae in in vitro studies. However, there has been no studies evaluating the combined effect of pomegranate peel and probiotics on precancerous colonic lesions prevention by modulating both oxidative stress and intestinal dysbiosis. In this context, this study aimed to evaluate the chemopreventive effects of pomegranate peel separately or combined with probiotics, against alterations in the intestinal microbiota and oxidative stress associated with DMH-induced colon cancer in high-fat-diet fed Wistar rats.

## Materials and Methods

### Chemicals

To carry out this study, 1,2-dimethylhydrazine dihydrochloride (DMH), tripyridyl-s-triazine (TPTZ), N-acetylcysteine (NAC), 2,6-Di-tert-butyl-4-methylphenol (BHT), 5,5'-Dithiobis (2-nitrobenzoic acid) (DTNB), thiobarbituric acid (TBA), 1,1, 3, 3-tetraethoxypropane (TEP) and trichloroacetic acid (TCA), were purchased from Sigma-Aldrich Company, St. Louis, MO, USA. All other chemicals used in this study were of high quality.

### Plant Material

The pomegranate (*P. granatum* L.) fruit used in this study is known as "Séfri"; which comes from the region of Mostaganem (northwestern Algeria). The pomegranate peels were dried in dark at room temperature, then ground with a mechanical grinder (Pulverisette, Fritsch, Germany).

### Probiotics

Lactibiane Tolérance® (PiLeJe, Package Reference 14BX4 06-2016, France) is a dietary supplement containing  $4 \times 10^9$  CFU/g of lyophilized viable lactic acid bacteria. It is composed of five bacterial strains, namely *Bifidobacterium lactis* LA 303, *Lactobacillus acidophilus* LA 201, *Lactobacillus plantarum* LA 301, *Lactobacillus salivarius* LA 302 and *Bifidobacterium lactis* LA 304.

### Animals, Diets and Experimental Design

Thirty-six adult male Wistar rats ( $231.9 \pm 6.76$  g) were obtained from the Pasteur Institute in Algiers (Algeria). All rats were given a standard commercial diet (8.05% fat, 45.36% carbohydrates, and 19.07% proteins: 330.21 kcal/100 g) which purchased from the National Office of Livestock Feed (Rahwiya, Tiaret, Algeria). Rats were kept for 2 weeks in an air-conditioned room at  $22 \pm 1^\circ\text{C}$  and  $55 \pm 10\%$  relative humidity with a standard 12-hour light-dark cycle in order to stabilize all metabolic conditions. All the experiments were carried out according to the guidelines of the Institutional Animal Care Committee of the Algerian Higher Education and Scientific Research (Agreement Number 45/DGLPAG/DVA.SDA.14).

Specific diet namely high-fat diet (HFD) containing 48% animal fat of ovine origin, 6.1% carbohydrates and 20% proteins (591.93 kcal/100 g) was also used in the present trial protocol. The DMH (Sigma Chemical Co., St. Louis, MO, USA) was administered by subcutaneous injection at 30 mg/kg body weight (b.w.), once a week, for a period of 9 weeks. Animal weights were checked twice a week. After this acclimation period, these rats were divided into 6 groups (6 rats per group) as shown in Table 1.

The animals were anesthetized and sacrificed after 16 weeks of experiment. Blood samples were collected through cardiac puncture. The plasma was then recovered for the determination of biochemical and oxidative parameters.

**Table 1.** Animal Experimental Design

Groups	Treatments
G1	Fed a standard diet
G2	Fed a High fat diet (HFD) + saline solution injection (0.9%)
G3	Fed a standard diet + DMH subcutaneous injection (30 mg/kg body weight, once a week for 9 weeks)
G4	Fed a HFD + DMH subcutaneous injections (30 mg/kg b.w. once a week for 9 weeks)
G5	DMH subcutaneous injections (30 mg/kg b.w. once a week for 9 weeks) + Fed a HFD supplemented with pomegranate peel (2.5 g/100 g diet)
G6	DMH subcutaneous injections (30 mg/kg b.w. once a week for 9 weeks) + Fed a HFD+2.5% (w/w) pomegranate peel and probiotics Lactibiane Tolérance® ( $4 \times 10^9$ CFU/kg diet)

### Biochemical Parameters Determination

Total cholesterol (Chol), high density lipoprotein cholesterol (HDL-C), low density lipoprotein cholesterol (LDL-C), alanine Aminotransferase (ALT) and aspartate aminotransferase (AST) were assayed by colorimetric and enzymatic methods (Spinreact, Sant Esteve De Bas, Spain) according to Durand and Beaudeau.<sup>19</sup>

### Measurement of the Ferric Reducing Ability of Plasma

The total plasma reducing power was evaluated using the technique described by Benzi and Strain.<sup>20</sup> This method was developed using TPTZ reagent (Sigma Aldrich, Germany). A standard curve was obtained from a stock solution of FeSO<sub>4</sub>·7H<sub>2</sub>O at 1 mM. Then, 100 µL of the sample solution were added to 900 µL of ferric reducing ability of plasma (FRAP) solution. Afterwards, the absorbance readings of the samples were performed by spectrometry at 593 nm, after 30 minutes of incubation at 37°C.

### Protein Oxidation Assay - Thiol Groups

The oxidation of proteins was determined according to the method of Faure and Lafond<sup>21</sup> by measuring the thiol groups in the plasma. The standard curve was obtained using a solution of NAC (1 mM). Then, a sample of 250 µL was added to 750 µL of phosphate buffer (pH=8) and 250 µL of DTNB (Sigma Aldrich, Germany). The mixture was left in the dark for 15 minutes, then, the absorbance was read at 412 nm.

### Evaluation of Lipid Peroxidation

This assay was performed on plasma. To do so, 800 µL of a mixture TBA at 0.375% (w/v), TCA (20%), BHT (0.01%) and hydrogen chloride (HCl) 1N were added to 200 µL of the sample solution. After stirring for 2 minutes, the mixture was incubated in a water bath at 100°C for 15 minutes. To stop the reaction, the tubes were placed in ice, and the complex thus obtained was extracted with butanol during 2 minutes. After centrifugation at 4000 rpm for 10 minutes at 4°C (Sigma, 3K10, Laborzentrifugen, Germany), the supernatant was taken and the absorbance of the pink chromogen obtained was measured at 532 nm using UV/visible light spectrophotometer (Shimadzu 1240, Japan). In addition, the plasma malondialdehyde (MDA) concentration was calculated using a standard curve of TEP.<sup>22</sup>

### Histopathological Analysis

The colons were removed, and were then rinsed with 0.9% NaCl solution. Next, the colons were opened longitudinally and placed on filter paper strips, and directly fixed in 10% formalin for 24 hours and then dehydrated in ascending concentrations of ethanol. After dehydration, the specimens were cleared in xylene and then embedded in paraffin. Some paraffin tissue blocks were cut into microscopic sections of thickness 5 microns using a microtome (Leika RM2145, Germany). The obtained tissue sections were collected and placed on glass slides, which were stained with hematoxylin and eosin for histopathological examination using a light microscope (Zeiss, Germany) according to Bancroft and Gamble.<sup>23</sup>

### Microbiological Analysis

To assess the effect of pomegranate peel and probiotics on the intestinal microbiota composition, some faecal bacteria were enumerated such as *Lactobacillus* spp., *Bifidobacterium* spp., *Escherichia coli* and *Bacteroides* spp. This method consists in dissolving 1g of fresh feces in 9 mL of 0.9% physiological saline solution. Ten-fold dilutions were prepared in the same diluent. Then, 0.1 mL of the diluted aliquot sample was spread on the surface of MacConkey agar for *E. coli*. All plates were incubated at 37°C for 24 hours.<sup>24</sup> This is while the enumeration of *Bacteroides*, *Lactobacillus* and *Bifidobacterium* was realized by pour plate method using Bacteroides Bile Esculin (BBE) agar + kanamycin, MRS agar and MRS + 0.5% cysteine-HCl, respectively and the incubation was realized under anaerobic conditions using the GasPak (AnaeroGen™, Oxoid, Basingstoke, UK) at 37°C for 48 to 72 hours. The viable counts were expressed as the log<sub>10</sub> of colony forming units (CFU/g) of faeces.

### Statistical Analyses

All the obtained results are presented in the form of means ± standard error of three determinations in triplicate. The statistical analysis of data was achieved using the STATISTICA software (version 6.1, StatSoft, Tulsa, OK, USA). Statistical comparisons were performed using one-way analysis of variance (ANOVA), followed by post hoc Tukey's test.

A value of  $P < 0.05$  was used as the significance threshold.

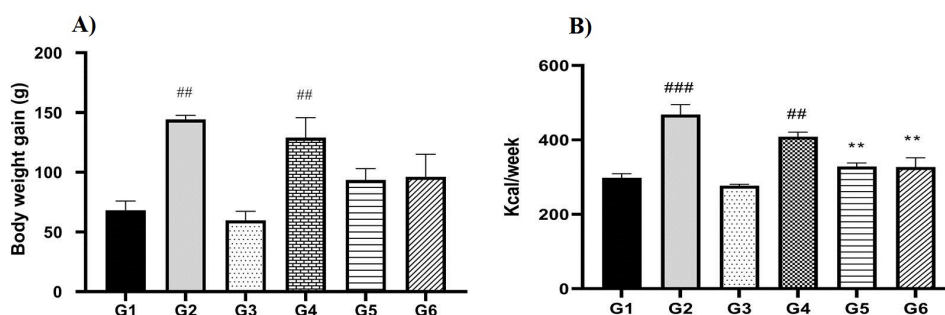
## Results

### Effect of Pomegranate Peel Combined or not with Probiotics on Weight Gain and Energy Intake

The results showed a significant difference ( $P < 0.01$ ) between the weight gain of the HFD groups (G2 and G4) and the control groups (G1 and G3). However, treatment of rats with pomegranate peel combined or not with probiotics decreased the weight gain by 26% and 28%, in animals from the G5 and G6 groups, respectively, in comparison to the HFD + DMH positive control group (G4). Similarly, a significant ( $P < 0.01$ ) difference in energy intake was also noted between G5 ( $328.72 \pm 9.23$  kcal) and G6 ( $327.08 \pm 25.02$  kcal) respectively compared to G4 ( $408.6 \pm 12.5$  kcal). Results are shown in Figure 1.

### Effect of Pomegranate Peel Alone or in Combination with Probiotics on the Biochemical Parameters

Dietary supplementation with pomegranate peel combined or not with probiotics, induced variations in the biochemical parameters. Results obtained with rats of G5 (HFD-Peel + DMH) and G6 (HFD-Peel-Probiotics + DMH) groups, indicated a significant decrease ( $P < 0.001$ ) in cholesterol levels of 36% and 40%, and LDL-C levels of 48% and 64%, respectively, in comparison with rats of G4 (HFD + DMH) positive control group. Furthermore triglyceride contents significantly ( $P < 0.05$ ) decreased in the G5 (26%) and G6 (29%) groups of rats as clearly shown in Table 1. The results also showed a very significant decrease ( $P < 0.01$ ) in the plasma content of ASAT and ALAT in HFD-Peel + DMH and HFD-Peel-Probiotics + DMH groups in comparison with the



**Figure 1.** Effect of Pomegranate Peel Alone or Combined With Probiotics on (A) Body Weight Gain (g); (B) Energy Intake (kcal/wk) of Different Groups of Rats After 16 Weeks of Experiment.

The results are expressed as means  $\pm$  SE (n = 6). G1: negative DMH-untreated control rats receiving standard diet (SD); G2: negative DMH-untreated control rats receiving high-fat diet (HFD); G3: positive DMH-treated control rats receiving SD; G4: positive DMH-treated control rats receiving HFD; G5 and G6 are DMH-treated and fed with 2.5% (w/w) powdered pomegranate peel-supplemented HFD diet in the presence of a mixture of probiotics for G6 only.  $^{***}P < 0.001$  and  $^{**}P < 0.01$  significant difference compared to negative DMH-untreated control group (G1).  $^{#}P < 0.01$  Significant difference compared to G4.

HFD + DMH group (Table 2).

### Effect of Pomegranate Peel and Probiotics on the Oxidative Parameters

#### Ferric Reducing Ability of Plasma

The results showed that the FRAP in rats of the two groups (G3 and G4), i.e. positive DMH-treated controls (SD and HFD) groups, was significantly lower ( $P < 0.01$ ) compared with that of the negative DMH-untreated control (SD and HFD) rat groups (G1 and G2). On the other hand, the incorporation of pomegranate peel into these experimental diets, supplemented or not with probiotics (G5 and G6) had a significant ( $P < 0.001$ ) impact on the FRAP content. Indeed, there was a significant increase in FRAP ( $P < 0.001$ ), which is estimated at 88% in the G5 (HFD-Peel + DMH) group, in comparison to the HFD positive DMH-treated control group (Figure 2a).

#### Evaluation of Plasma Protein Oxidation (SH Groups)

The evaluation of protein oxidation indicated that the supplementation of experimental diets (HFD) with pomegranate peel combined or not with probiotics induced

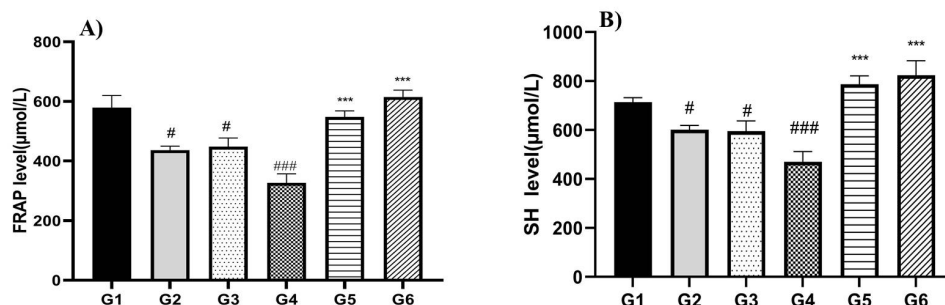
a very significant increase of 67 and 75% ( $P < 0.001$ ) in SH groups in the G5 (HFD-Peel + DMH) and G6 (HFD-Peel Probiotics DMH), respectively, in comparison with the HFD positive DMH-treated control group (G4) as reported in Figure 2b.

#### Plasma Lipid Peroxidation (Malondialdehyde Level)

The results of lipid peroxidation evaluation are shown in Figure 3. They indicated that DMH-treatment induced a significant increase ( $P < 0.001$ ) in plasma MDA concentrations in rat fed with a standard diet (G1) or with a high fat (G2) diet. These concentrations were very different from those recorded in negative DMH-untreated control (SD and HFD) groups (G1 and G2). However, high significant reduction ( $P < 0.001$ ) in MDA levels was observed in G5 (HFD-Peel + DMH) (55%). Similarly, the administration of probiotic decreased the MDA level (66%) in comparison with HFD positive DMH-treated control group (G4).

#### Histopathological Study

Histopathological examination of colons from negative DMH-untreated control rats (G1 and G2 groups), exhibited a



**Figure 2.** Effect of Pomegranate Peel Alone or in Combination With Probiotics on (A) FRAP Level ( $\mu\text{mol/L}$ ) and (B) Thiol Groups Level in Plasma of the Different Groups of Rats After 16 Weeks.

The results are expressed as means  $\pm$  SE (n = 6). G1: negative DMH-untreated control rats receiving standard diet (SD); G2: negative DMH-untreated control rats receiving high-fat diet (HFD); G3: positive DMH-treated control rats receiving SD; G4: positive DMH-treated control rats receiving HFD; G5 and G6 are DMH-treated and fed with 2.5% (w/w) powdered pomegranate peel-supplemented HFD diet in the presence of a mixture of probiotics for G6 only.  $^{***}P < 0.001$  and  $^{#}P < 0.05$  significant difference compared to negative DMH-untreated control group (G1).  $^{***}P < 0.001$  Significant difference compared to G4. Abbreviations: FRAP, ferric reducing ability of Plasma; SH, Sulfhydryl group.

**Table 2.** Plasma Cholesterol, Triglyceride, HDL-C, LDL-C, AST and ALT Levels in Different Rat Groups After 16 Weeks of Experiment

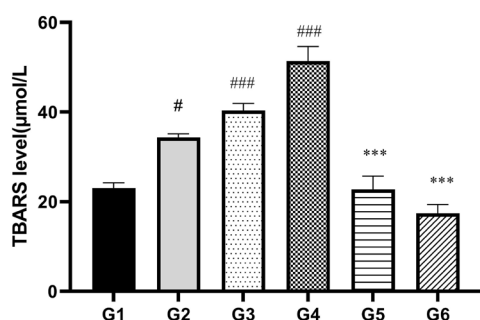
Groups	Chol (g/L)	LDL (g/L)	HDL-C (g/L)	TG (g/L)	AST (IU/L)	ALT (IU/L)
G1	0.53±0.11	0.16±0.44	0.53±0.55	0.52±0.06	119±6.61	57.37±2.88
G2	1.45±0.3 <sup>***</sup>	0.29±0.01 <sup>**</sup>	0.63±0.09	0.99±0.13 <sup>**</sup>	143±17.82 <sup>‡</sup>	91.78±2.89 <sup>**</sup>
G3	0.84±0.06	0.17±0.02	0.63±0.01	1.14±0.05 <sup>***</sup>	118.57±11	88.09±9.02 <sup>**</sup>
G4	1.07±0.1 <sup>**</sup>	0.25±0.04	0.53±0.05	1.08±0.08 <sup>***</sup>	145.38±10.47 <sup>‡</sup>	107.34±12.9 <sup>**</sup>
G5	0.68±0.03 <sup>*</sup>	0.13±0.03 <sup>**</sup>	0.62±0.06	0.76±0.15 <sup>*</sup>	110.71±5.65 <sup>**</sup>	55.05±2.24 <sup>***</sup>
G6	0.74±0.06 <sup>*</sup>	0.09±0.03 <sup>**</sup>	0.56±0.03	0.85±0.09 <sup>*</sup>	111.25±5.20 <sup>**</sup>	61.88±1.23 <sup>***</sup>

Abbreviations: CHL: Cholesterol; HDL-C: high density lipoprotein cholesterol; LDL-C: low density lipoprotein cholesterol; TG: triglyceride; AST: aspartate aminotransferase; ALT: alanine aminotransferase.

The results are expressed as means ± SE (n = 6). G1: negative DMH-untreated control rats receiving standard diet (SD); G2: negative DMH-untreated control rats receiving high-fat diet (HFD); G3: positive DMH-treated control rats receiving SD; G4: positive DMH-treated control rats receiving HFD; G5 and G6 are DMH-treated and fed with 2.5% (w/w) pomegranate peel and supplemented HFD diet in the presence of probiotics for G6 only.

<sup>\*\*\*</sup>P<0.001, <sup>\*\*</sup>P<0.01 and <sup>‡</sup>P<0.05 significant difference compared to G1.

<sup>\*\*\*</sup>P<0.001, <sup>\*\*</sup>P<0.01 and <sup>‡</sup>P<0.05 significant difference compared to G4.



**Figure 3.** Effect of Pomegranate Peel Alone or in Combination With Probiotics on Plasma Lipid Peroxidation (µmol/L) Levels in Different Groups of Rats After 16 Weeks.

The results are expressed as means ± SE (n = 6). G1: negative DMH-untreated control rats receiving standard diet (SD); G2: negative DMH-untreated control rats receiving high-fat diet (HFD); G3: positive DMH-treated control rats receiving SD; G4: positive DMH-treated control rats receiving HFD; G5 and G6 are DMH-treated and fed with 2.5% (w/w) powdered pomegranate peel-supplemented HFD diet in the presence of a mixture of probiotics for G6 only. <sup>\*\*\*</sup>P<0.001 and <sup>‡</sup>P<0.05 significant difference compared to negative DMH-untreated control group (G1). <sup>\*\*\*</sup>P<0.001 significant difference compared to G4. Abbreviation: TBARS, thiobarbituric acid reactive substances.

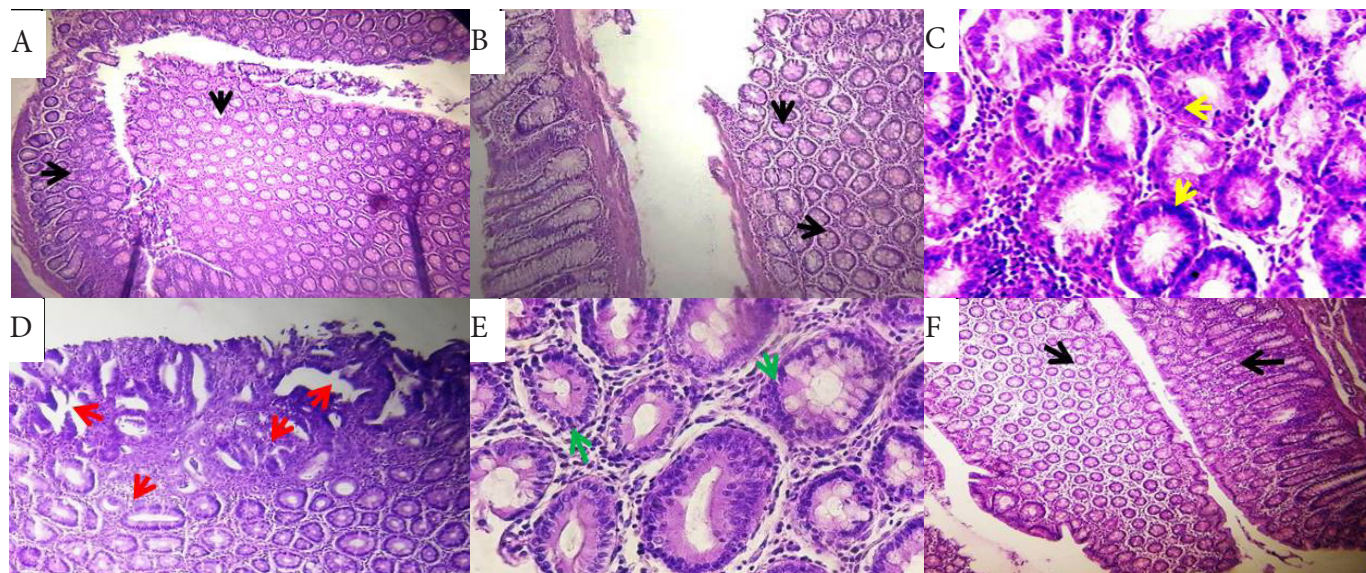
homogeneous histological architecture, with a normal colonic mucosa, consisting of glands of homogeneous structure (Figure 4A-B). However, the HFD positive DMH-treated control group (G4) revealed either intra-mucosal carcinoma or high-grade dysplasia (Figure 4D). This dysplasia was characterized by disorganized crypt architecture, nuclear stratification reaching the apical side of cells, loss of mucosecretion and presence of mitotic figures. Moreover, in some rats belonging to the group G5 (HFD-Peel + DMH) (see Figure 4E), colons exhibited low-grade dysplasia, in comparison with those in group G4. However, in the last group (G6) (HFD-Peel-Probiotics + DMH), the incorporation of pomegranate peel and probiotics in the diet allows restoring the normal histological appearance of the colonic mucosa, which exhibited a homogenous gland structure, in comparison with rats in group G4, as seen in Figure 4F.

### Microbial Analysis

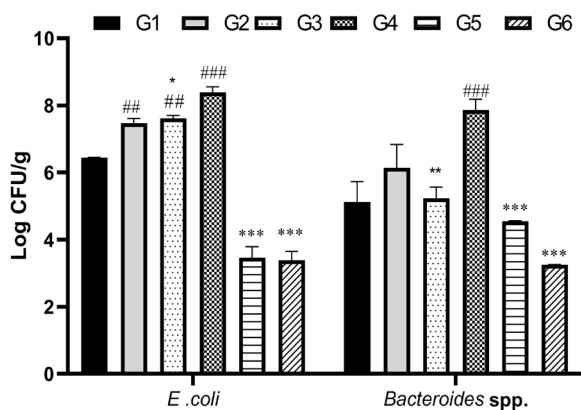
The results revealed a highly significant decrease ( $P<0.001$ ) in the number of *E. coli* (58%) and *Bacteroides* spp. (42%) in HFD diet supplemented with pomegranate peel group (G5) in comparison to the HFD positive DMH-treated control group (G4). Similarly, during this experiment, a 60 and 58% reduction in the count of *E.coli* and *Bacteroides* spp., respectively, was observed after the administration of probiotics in G6, as compared with the G4 (Figure 5). On the other side, the highest count ( $11.87 \pm 0.25 \log_{10}$  CFU/g ;  $P<0.001$ ) of *Lactobacillus* spp. was detected in the G5 group as compared with that of the G4 ( $6.48 \pm 0.05 \log_{10}$  CFU/g). Moreover, the diet supplemented with pomegranate peel led to a highly significant ( $P<0.001$ ) increase in the amount of *Bifidobacterium*, which is estimated at 52% in the group fed the HFDP diet (G5), as compared with those of G4. In addition, the incorporation of probiotics in a high-fat diet (G6) induced an increase in the counts of *Lactobacillus* and *Bifidobacterium*, which is estimated at 7% and 43%, respectively, in comparison to HFD positive DMH-treated control group (G4), as shown in Figure 6.

### Discussion

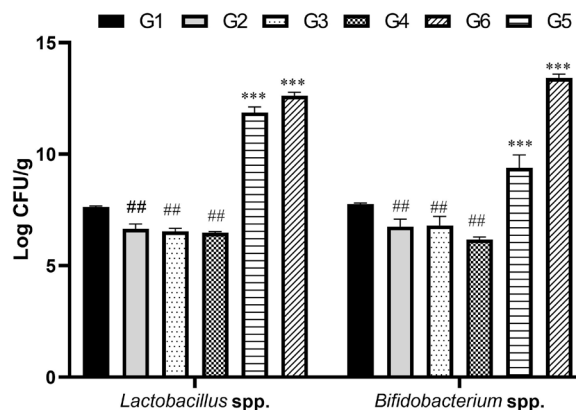
The current study was done to assess the effect of a combined treatment of pomegranate peel powder and probiotics on rat colon carcinogenesis. The administration of the pomegranate peel to a high fat diet combined or not with probiotics induced a reduction in the levels of plasma biochemical parameters. Thus, these results are in agreement with those reported by Hossin<sup>25</sup> who confirmed that pomegranate peel improved the plasma lipid profile and significantly reduced triglyceride, total cholesterol and LDL-cholesterol contents in rats fed with a high-fat diet. This decrease may be due to the beneficial effect of the bioactive compounds, i.e. polyphenols and dietary fiber, of pomegranate peels. The results of the present support previous studies that the administration of probiotics lead to a decrease in plasma cholesterol levels in rats subjected to a HFD diet.<sup>26</sup> In addition, polyphenols could modify the number and type of bacteria that constitute the intestinal microflora, which use these bioactive molecules to produce different secondary metabolites such as dihydroxyphenyl acid, phenylpropionic acid, and urolithin.<sup>16,27</sup> These metabolites are



**Figure 4.** Photomicrographs of Histological Sections of Rats Colon After 16 Weeks of Treatment. Histological sections of normal colon from (black arrow) (A) negative DMH-untreated control rats receiving standard diet (G1) negative DMH-untreated control rats receiving HFD (G2) (H&E,10×); (C) A microscopic section of colon from positive DMH-treated control rats receiving SD (G3) shows a high-grade dysplasia (yellow arrow) (H&E,40×), (D) Histological sections of colon from positive DMH-treated control rats receiving HFD (G4) represents an intramucosal carcinoma (red arrow) (H&E, 10×); (E) A microscopic section of colon from DMH-treated rats and fed with 2.5% (w/w) powdered pomegranate peel-supplemented HFD (G5); demonstrates a low grade dysplasia (green arrow) (H&E, 40×), (F) Histological section of colon from HFD-Peel-Probiotics + DMH group (G6) (black arrow) (H&E, 10×).



**Figure 5.** Influence of Pomegranate Peel Combined or Not With Probiotics on the Number of *E. coli* and *Bacteroides* spp. The results are expressed as means ± SE (n = 6). G1: negative DMH-untreated control rats receiving standard diet (SD); G2: negative DMH-untreated control rats receiving high-fat diet (HFD); G3: positive DMH-treated control rats receiving SD; G4: positive DMH-treated control rats receiving HFD. G5 and G6 are DMH-treated and fed with 2.5% (w/w) powdered pomegranate peel-supplemented HFD diet in the presence of a mixture of probiotics for G6 only. <sup>###</sup>*P*<0.001 and <sup>\*\*</sup>*P*<0.01 significant difference compared to negative DMH-untreated control group (G1). <sup>\*\*\*</sup>*P*<0.001, <sup>\*</sup>*P*<0.05 and <sup>\*\*</sup>*P*<0.01 significant difference compared to G4. Abbreviation: CFU, colony forming unit.



**Figure 6.** Influence of Pomegranate Peel Combined or Not With Probiotics on the Number of *Lactobacillus* spp., and *Bifidobacterium* spp. in Rats During the 16 Weeks of Treatment. The results are expressed as means ± SE (n = 6). G1: negative DMH-untreated control rats receiving standard diet (SD); G2: negative DMH-untreated control rats receiving high-fat diet (HFD); G3: positive DMH-treated control rats receiving SD; G4: positive DMH-treated control rats receiving HFD. G5 and G6 are DMH-treated and fed with 2.5% (w/w) powdered pomegranate peel-supplemented HFD diet in the presence of a mixture of probiotics for G6 only. <sup>###</sup>*P*<0.001 and <sup>\*\*</sup>*P*<0.01 significant difference compared to negative DMH-untreated control group (G1). <sup>\*\*\*</sup>*P*<0.001 significant difference compared to G4. Abbreviation: CFU, colony forming unit

easily absorbed by the intestine and have greater antioxidant and anti-inflammatory activities than the polyphenols that generated them.<sup>28</sup> These secondary derivatives are able to influence the lipid metabolism by promoting their excretion in feces, and thereby lowering the plasma cholesterol levels in hypercholesterolemic rats.<sup>29</sup> Results also showed a decrease in plasma transaminase (AST and ALT) levels in the HFD-Peel-Probiotics + DMH group as compared with those in the HFD positive DMH-treated control group. These results are consistent with those obtained by Sadeghipour et al<sup>30</sup> who indicated that pomegranate peel ethanolic extract reduce the AST and ALT plasma levels in Wistar rats fed with a lipid-enriched diet.

The results of the oxidative parameters are consistent with those reported by Perše and Cerar<sup>31</sup> who established that the hyperlipidic diet in DMH-treated rats decreased the total plasma antioxidant defense capacity, resulting in a change in the oxidative status. Indeed, a study claimed that chemically induced colon cancer in experimental models caused not only excessive production of free radicals, but also a decrease in antioxidant defense capacities due to the decreased activity of certain antioxidant enzymes.<sup>32</sup> This disorder in the oxidant/antioxidant balance could be related to the secondary metabolite, resulting from DMH metabolic activation in the liver and colon by intestinal microflora.<sup>33</sup> It was also reported that HFD supplemented with pomegranate peel and probiotics enhanced the protection against the protein thiol oxidation and lipid peroxidation. Recently, Salwe et al<sup>34</sup> suggested that pomegranate peel has a powerful antioxidant power due to its polyphenols and flavonoids, such as the ellagic acid and punicalagin which have the capacity to decrease the lipids peroxidation. It is now well established that there is a close link between the inflammatory status and oxidative stress during the development of colon cancer.<sup>35</sup> This observation could explain the antioxidant effect of pomegranate peel polyphenols, via their anti-inflammatory activity as previously demonstrated by Larrosa et al<sup>36</sup> who revealed that ellagic acid had an antiproliferative effect, which resulted in G1 cell-cycle arrest and in the induction of apoptosis as well. Besides, this experiment suggested that administration of pomegranate peel and probiotics allows restoring the normal histological appearance of the colon, which confirmed the absence of tumor and the disappearance of signs of dysplasia in colonic crypts. Protection against the development of colon carcinogenesis using pomegranate peel can be explained by its pro-apoptotic potential. Recently, an experimental study has revealed that pomegranate peel extracts induce apoptosis, reduce inflammation and therefore inhibit the proliferation of tumor cells.<sup>37</sup> Furthermore, it has been widely established that probiotics had an impact on immune and cellular responses through various mechanisms involving the strengthening of the epithelial barrier, and the stimulation of anti-inflammatory parameters, antioxidant and anti-carcinogenic compounds.<sup>24,38</sup> Some probiotic strains, such as *Lactobacilli*, can exert an immunomodulatory effect through the induction of regulatory activity of T lymphocytes, and stimulation of the phagocytic and bactericidal activities of neutrophils and the natural killer cell activity which is involved in the suppression

of tumorigenesis.<sup>39</sup> On the other hand, Urbanska et al<sup>40</sup> reported that the possible immunomodulatory property of the probiotic *Lactobacillus acidophilus* is closely linked to reduced risks of intestinal tumors, dysplasia and inflammation. The mechanism involved in this phenomenon is related to the dysfunction of protein kinase activity which is regulated by extracellular signals.

Moreover, probiotic strains can modulate the profile of the intestinal microbiota whose composition variation are widely involved in colonic carcinogenesis. In this study, dietary supplementation with pomegranate peel and probiotics had an influence on the microbial profile of the intestinal microflora of DMH-treated rats; this is confirmed by the decrease in the number of *E. coli* in animals of this group. This decrease is revealed in the beneficial effect of bioactive compounds, such as polyphenols and dietary fibers, contained in pomegranate peel. It is clearly established that polyphenols can modify the microbiota composition by restoring it via its antibacterial and prebiotic effect.<sup>41</sup> Reddy et al<sup>42</sup> suggested that punicalagins of pomegranate peel exert antimicrobial activity by inhibiting the growth of many pathogenic bacteria, essentially *E. coli*, which is a bacterium that has the capacity to produce colibactin toxin. This toxin is characterized by a clastogenic potential and it causes double-strand breaks of DNA in intestinal cells, thus triggering a chromosomal instability which can turn healthy cells into cancer cells.<sup>43</sup> Furtherly, Bialonska et al<sup>44</sup> reported that pomegranate polyphenols (ellagitannins) inhibit the growth of *Bacteroides fragilis* in a dose-response relationship. This antimicrobial activity can be explained by the intestinal luminal pH decrease caused by polyphenols, which significantly affect the intestinal profile. Moreover, other studies showed that high dietary fiber intake caused a large production of short chain fatty acids, which are capable of decreasing the intestinal pH which prevented the growth of potentially pathogenic bacteria, such as *E. coli* and other bacteria of the family *Enterobacteriaceae*.<sup>45</sup>

This study indicated that powder of pomegranate peel significantly increased the amount of *Lactobacillus* spp. in the fecal samples of DMH-treated rats. This increase can be explained by the combination of two effects; the first one is related to the fact that pomegranate peel selectively stimulates *Lactobacillus* spp. and *Bifidobacterium* spp. through the prebiotic activity<sup>41</sup>; while the second one is related to the beneficial nature of probiotic bacteria. These findings corroborate those reported by Thirabunyanon and Hongwittayakorn<sup>46</sup> who established that *Lactobacillus salivarius*, has antiproliferative properties by adhering directly to colon cancer cells, thus triggering the production of butyric acid and other short chain fatty acids.

## Conclusions

The results of the present study revealed that pomegranate peel, combined with or without probiotics, have a remarkable effect on the modulation of oxidative stress and intestinal dysbiosis of DMH-treated rats. These findings also suggested that pomegranate peel powder and probiotics would act as a potential chemopreventive agent against chemically induced preneoplastic colonic lesions.

### Authors' Contributions

RB carried out the experiment, was responsible for the experimental design and results interpretation, coordinated data analysis and wrote the paper. RB participated in the design of the study and performed the oxidative parameters. HH contributed to the interpretation of the histopathological results. SB aided in the statistical study. AR directed, coordinated and took the lead in writing the manuscript.

### Conflict of Interest Disclosures

The authors declare no conflicts of interest.

### Acknowledgements

This work was supported by a grant from the Algerian Ministry of Higher Education and Scientific Research.

### References

- Bhandari A, Woodhouse M, Gupta S. Colorectal cancer is a leading cause of cancer incidence and mortality among adults younger than 50 years in the USA: a SEER-based analysis with comparison to other young-onset cancers. *J Investig Med*. 2017;65(2):311-315. doi:10.1136/jim-2016-000229.
- Cohen C, Cardoso JF, Garcia SB, Vannucchi H. Vitamin E supplementation in chemical colorectal carcinogenesis: a two-edged knife. *Nutrients*. 2014;6(8):3214-3229. doi:10.3390/nu6083214.
- Reddy BS. Dietary fat and colon cancer: animal model studies. *Lipids*. 1992;27(10):807-813. doi:10.1007/bf02535855.
- Järvinen R, Knekt P, Hakulinen T, Rissanen H, Heliövaara M. Dietary fat, cholesterol and colorectal cancer in a prospective study. *Br J Cancer*. 2001;85(3):357-361. doi:10.1054/bjoc.2001.1906.
- Srihari T, Balasubramanian V, Nalini N. Role of oregano on bacterial enzymes in 1,2-dimethylhydrazine-induced experimental colon carcinogenesis. *Can J Physiol Pharmacol*. 2008;86(10):667-674. doi:10.1139/y08-071.
- Trindade de Paula M, Poetini Silva MR, Machado Araujo S, et al. High-fat diet induces oxidative stress and MPK2 and HSP83 gene expression in *Drosophila melanogaster*. *Oxid Med Cell Longev*. 2016;2016:4018157. doi:10.1155/2016/4018157.
- Jucá MJ, Bandeira BC, Carvalho DS, Leal AT. Comparative study of 1,2-dimethylhydrazine and azoxymethane on the induction of colorectal cancer in rats. *J Coloproctol*. 2014;34(3):167-173. doi:10.1016/j.jcol.2014.06.003.
- Collins D, Hogan AM, Winter DC. Microbial and viral pathogens in colorectal cancer. *Lancet Oncol*. 2011;12(5):504-512. doi:10.1016/s1470-2045(10)70186-8.
- Lin C, Cai X, Zhang J, et al. Role of gut microbiota in the development and treatment of colorectal cancer. *Digestion*. 2019;100(1):72-78. doi:10.1159/000494052.
- Roller M, Pietro Femia A, Caderni G, Rechkemmer G, Watzl B. Intestinal immunity of rats with colon cancer is modulated by oligofructose-enriched inulin combined with *Lactobacillus rhamnosus* and *Bifidobacterium lactis*. *Br J Nutr*. 2004;92(6):931-938. doi:10.1079/bjn20041289.
- Nishino Y, Suzuki Y, Ohmori K, et al. Cancer incidence profiles in the Miyagi Cohort Study. *J Epidemiol*. 2004;14 Suppl 1:S7-11. doi:10.2188/jea.14.s7.
- Reid G. Probiotics: definition, scope and mechanisms of action. *Best Pract Res Clin Gastroenterol*. 2016;30(1):17-25. doi:10.1016/j.bpg.2015.12.001.
- Roberfroid MB. Chicory fructooligosaccharides and the gastrointestinal tract. *Nutrition*. 2000;16(7-8):677-679. doi:10.1016/s0899-9007(00)00244-6.
- Liu H, Liu X, Zhang C, et al. Redox imbalance in the development of colorectal cancer. *J Cancer*. 2017;8(9):1586-1597. doi:10.7150/jca.18735.
- Karimi M, Sadeghi R, Kokini J. Pomegranate as a promising opportunity in medicine and nanotechnology. *Trends Food Sci Technol*. 2017;69(Pt A):59-73. doi:10.1016/j.tifs.2017.08.019.
- Cortés-Martín A, García-Villalba R, González-Sarrías A, et al. The gut microbiota urolithin metabolites revisited: the human metabolism of ellagic acid is mainly determined by aging. *Food Funct*. 2018;9(8):4100-4106. doi:10.1039/c8fo00956b.
- Nozohour Y, Golmohammadi R, Mirnejad R, Fartashvand M. Antibacterial activity of pomegranate (*Punica granatum* L.) seed and peel alcoholic extracts on *Staphylococcus aureus* and *Pseudomonas aeruginosa* isolated from health centers. *J Appl Biotechnol Rep*. 2018;5(1):32-36. doi:10.29252/jabr.01.01.06.
- Li Z, Summanen PH, Komoriya T, et al. Pomegranate ellagitannins stimulate growth of gut bacteria in vitro: implications for prebiotic and metabolic effects. *Anaerobe*. 2015;34:164-168. doi:10.1016/j.anaerobe.2015.05.012.
- Durand G, Beaudeau JL. *Biochimie Médicale: Marqueurs Actuels et Perspectives*. Paris: Médecine Sciences Publications-Lavoisier; 2011. p. 144.
- Benzie IF, Strain JJ. The ferric reducing ability of plasma (FRAP) as a measure of "antioxidant power": the FRAP assay. *Anal Biochem*. 1996;239(1):70-76. doi:10.1006/abio.1996.0292.
- Faure P, Lafond JL. Measurement of plasma sulfhydryl and carbonyl groups as a possible indicator of protein oxidation. In: Favier AE, Cadet J, Kalyanaraman B, Fontecave M, Pierre JL, eds. *Analysis of Free Radicals in Biological Systems*. Basel: Birkhäuser; 1995:237-248. doi:10.1007/978-3-0348-9074-8\_17.
- Yagi K. A simple fluorometric assay for lipoperoxide in blood plasma. *Biochem Med*. 1976;15(2):212-216. doi:10.1016/0006-2944(76)90049-1.
- Bancroft JD, Gamble M. *Theory and Practice of Histological Techniques*. 6th ed. London: Churchill Livingstone; 2008. p. 724.
- Chang JH, Shim YY, Cha SK, Reaney MJT, Chee KM. Effect of *Lactobacillus acidophilus* KFR1342 on the development of chemically induced precancerous growths in the rat colon. *J Med Microbiol*. 2012;61(Pt 3):361-368. doi:10.1099/jmm.0.035154-0.
- Hossin FLA. Effect of pomegranate (*Punica granatum*) peels and its extract on obese hypercholesterolemic rats. *Pak J Nutr*. 2009;8(8):1251-1257. doi:10.3923/pjn.2009.1251.1257.
- El-Shafie HA, Yahia NI, Ali HA, Khalil FA, El-Kady EM, Moustafa YA. Hypocholesterolemic action of *Lactobacillus plantarum* NRRL-B-4524 and *Lactobacillus paracasei* in mice with hypercholesterolemia induced by diet. *Aust J Basic Appl Sci*. 2009;3(1):218-228.
- Rowland I, Gibson G, Heinken A, et al. Gut microbiota functions: metabolism of nutrients and other food components. *Eur J Nutr*. 2018;57(1):1-24. doi:10.1007/s00394-017-1445-8.
- Ito H. Metabolites of the ellagitannin geraniin and their antioxidant activities. *Planta Med*. 2011;77(11):1110-1115. doi:10.1055/s-0030-1270749.
- Selma MV, González-Sarrías A, Salas-Salvadó J, et al. The gut microbiota metabolism of pomegranate or walnut ellagitannins yields two urolithin-metabotypes that correlate with cardiometabolic risk biomarkers: comparison between normoweight, overweight-obesity and metabolic syndrome. *Clin Nutr*. 2018;37(3):897-905. doi:10.1016/j.clnu.2017.03.012.
- Sadeghipour A, Eidi M, Ilchizadeh Kavani A, Ghahramani R, Shahabzadeh S, Anissian A. Lipid lowering effect of *Punica granatum* L. peel in high lipid diet fed male rats. *Evid Based Complement Alternat Med*. 2014;2014:432650. doi:10.1155/2014/432650.
- Perše M, Cerar A. Morphological and molecular alterations in 1,2 dimethylhydrazine and azoxymethane induced colon carcinogenesis in rats. *J Biomed Biotechnol*. 2011;2011:473964. doi:10.1155/2011/473964.
- Hamiza OO, Rehman MU, Tahir M, et al. Amelioration of 1,2 dimethylhydrazine (DMH) induced colon oxidative stress, inflammation and tumor promotion response by tannic acid in Wistar rats. *Asian Pac J Cancer Prev*. 2012;13(9):4393-4402. doi:10.7314/apjcp.2012.13.9.4393.
- Thangaraj K, Natesan K, Settu K, et al. Orientin mitigates 1,2-dimethylhydrazine induced lipid peroxidation, antioxidant and biotransforming bacterial enzyme alterations in experimental rats. *J Cancer Res Ther*. 2018;14(6):1379-1388. doi:10.4103/jcrt.JCRT\_1363\_16.
- Salwe KJ, Sachdev DO, Bahurupi Y, Kumarappan M. Evaluation of antidiabetic, hypolipidemic and antioxidant activity of hydroalcoholic extract of leaves and fruit peel of *Punica granatum* in male Wistar albino rats. *J Nat Sci Biol Med*. 2015;6(1):56-62. doi:10.4103/0976-9668.149085.



35. Reuter S, Gupta SC, Chaturvedi MM, Aggarwal BB. Oxidative stress, inflammation, and cancer: how are they linked? *Free Radic Biol Med.* 2010;49(11):1603-1616. doi:10.1016/j.freeradbiomed.2010.09.006.
36. Larrosa M, Tomás-Barberán FA, Espín JC. The dietary hydrolysable tannin punicalagin releases ellagic acid that induces apoptosis in human colon adenocarcinoma Caco-2 cells by using the mitochondrial pathway. *J Nutr Biochem.* 2006;17(9):611-625. doi:10.1016/j.jnutbio.2005.09.004.
37. Ahmed HH, El-Abhar HS, Hassanin EAK, Abdelkader NF, Shalaby MB. *Punica granatum* suppresses colon cancer through downregulation of Wnt/ $\beta$ -Catenin in rat model. *Rev Bras Farmacogn.* 2017;27(5):627-635. doi:10.1016/j.bjpp.2017.05.010.
38. Toral M, Gómez-Guzmán M, Jiménez R, et al. The probiotic *Lactobacillus coryniformis* CECT5711 reduces the vascular pro-oxidant and pro-inflammatory status in obese mice. *Clin Sci (Lond).* 2014;127(1):33-45. doi:10.1042/cs20130339.
39. Sun J, Shi YH, Le GW, Ma XY. Distinct immune response induced by peptidoglycan derived from *Lactobacillus* sp. *World J Gastroenterol.* 2005;11(40):6330-6337. doi:10.3748/wjg.v11.i40.6330.
40. Urbanska AM, Bhatena J, Martoni C, Prakash S. Estimation of the potential antitumor activity of microencapsulated *Lactobacillus acidophilus* yogurt formulation in the attenuation of tumorigenesis in Apc(Min/+) mice. *Dig Dis Sci.* 2009;54(2):264-273. doi:10.1007/s10620-008-0363-2.
41. Neyrinck AM, Van Hée VF, Bindels LB, De Backer F, Cani PD, Delzenne NM. Polyphenol-rich extract of pomegranate peel alleviates tissue inflammation and hypercholesterolaemia in high-fat diet-induced obese mice: potential implication of the gut microbiota. *Br J Nutr.* 2013;109(5):802-809. doi:10.1017/s0007114512002206.
42. Reddy MK, Gupta SK, Jacob MR, Khan SI, Ferreira D. Antioxidant, antimalarial and antimicrobial activities of tannin-rich fractions, ellagitannins and phenolic acids from *Punica granatum* L. *Planta Med.* 2007;73(5):461-467. doi:10.1055/s-2007-967167.
43. Cuevas-Ramos G, Petit CR, Marcq I, Boury M, Oswald E, Nougayrède JP. *Escherichia coli* induces DNA damage in vivo and triggers genomic instability in mammalian cells. *Proc Natl Acad Sci U S A.* 2010;107(25):11537-11542. doi:10.1073/pnas.1001261107.
44. Bialonska D, Kasimsetty SG, Schrader KK, Ferreira D. The effect of pomegranate (*Punica granatum* L.) byproducts and ellagitannins on the growth of human gut bacteria. *J Agric Food Chem.* 2009;57(18):8344-8349. doi:10.1021/jf901931b.
45. Keddari S, Aldib I, Riazi A. In vivo stimulatory effects of wheat bran on intestinal microbial ecosystem of mice. *South Asian J Exp Biol.* 2014;4(1):24-32.
46. Thirabunyanon M, Hongwittayakorn P. Potential probiotic lactic acid bacteria of human origin induce antiproliferation of colon cancer cells via synergic actions in adhesion to cancer cells and short-chain fatty acid bioproduction. *Appl Biochem Biotechnol.* 2013;169(2):511-525. doi:10.1007/s12010-012-9995-y.